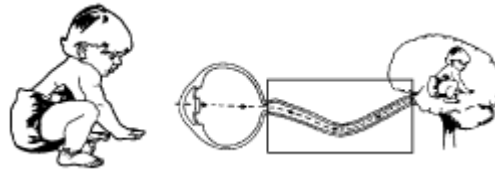


## OPTIC NERVE HYPOPLASIA



### DEFINITION

Optic Nerve Hypoplasia (ONH) refers to the underdevelopment of the optic nerve during pregnancy. The dying back of optic nerve fibers as the child develops in utero is a natural process, and ONH may be an exaggeration of that process. ONH may occur infrequently in one eye (unilateral) but more commonly in both eyes (bilateral). ONH is not progressive, is not inherited, and cannot be cured. ONH is one of the three most common causes of visual impairment in children.

### CAUSES

In most cases there is no known cause of ONH. Infrequently ONH has been associated with maternal diabetes, maternal alcohol abuse, maternal use of anti-epileptic drugs, and young maternal age (20 years of age or less), but these factors account for very few of the total number of cases. All races and socio-economic groups seem to be affected by ONH.

### CHARACTERISTICS

- ONH may occur by itself or along with neurological or hormonal abnormalities. Hormonal problems not apparent in early life may appear later.
- Children with ONH demonstrate a wide spectrum of visual function ranging from normal visual acuity to no light perception. The effect on the visual field may range from generalized loss of detailed vision in both central and peripheral fields (depressed visual fields) to subtle peripheral field loss.
- A high percentage of children with ONH have associated involuntary rhythmic movements of the eye (nystagmus). In most cases, the nystagmus is associated with significant bilateral reduced visual acuity.
- ONH is a stable condition. Visual function does not deteriorate with time. A mild improvement in visual function may occur as the result of maturation processes of the brain. In some cases, reduced nystagmus may also occur.
- Depth perception may be more severe if vision loss is great.
- Mild light sensitivity (photophobia) may occur.

## **DIAGNOSIS**

ONH is diagnosed by direct examination of the eye by an ophthalmologist. No current laboratory or radiographic tests will establish the diagnosis. Many infants who are diagnosed with Optic Nerve Atrophy are, in fact, children with ONH. Sometimes visual functioning can be predicted from the appearance of the optic discs. However, it is very difficult to predict visual acuity on this basis alone.

## **VISUAL AND BEHAVIORAL CHARACTERISTICS**

- The child's vision is characterized by a lack of detail (depressed field), but this lack of detail is not comparable to the blurred reduction in vision when a person removes her glasses.
- In certain cases of ONH a specific field defect occurs. Children may not be aware of people or objects in the periphery.
- Children with ONH may be unable to locate objects in space precisely due to a lack of depth perception.
- Some children with ONH have mild photophobia. These children may squint, lower their head, avoid light by turning away, or resist participating in outdoor activities.
- When one eye is affected more than the other, an ophthalmologist may recommend a trial of patching the stronger eye, since the visual loss may be due to amblyopia.
- Some feeding issues are associated with hormonal problems. Lack of interest in eating may be due to absent or diminished sense of smell and taste. Children with ONH may have very restricted food preferences. Some children exhibit excessive lip smacking while eating.
- Behaviors of some children with ONH may be due to associated medical conditions, such as inattentiveness and irritability due to low blood sugar levels (hypoglycemia).
- The child with associated central nervous system problems may be easily distracted, quickly frustrated and act in a disorganized or an impulsive way.

## CONDITIONS ASSOCIATED WITH ONH

Associated brain and hormonal abnormalities are common in children with nystagmus and bilateral severe vision loss, and are less common in cases where vision loss is mild or unilateral. Abnormalities include:

1. Midline anomalies of the brain: septo optic dysplasia (absence of the septum pellucidum and the corpus callosum), encephaloceles, anomalies of the ventricles, anencephaly, cerebral atrophy, and rarely, tumors.
2. Hormonal insufficiencies: thyroid, growth hormone, pituitary, adrenal, anti diuretic hormone (ADH).

Associated midline brain anomalies can be identified by either an MRI or CT scan. Hormonal insufficiencies require an examination by a specialist in hormonal disorders (pediatric endocrinologist). *Children particularly at risk for having associated hormonal insufficiencies are those who had neonatal low blood sugar (hypoglycemia), had prolonged jaundice (hyperbilirubinemia), failed to grow normally (failure to thrive), have difficulty regulating body temperature in connection with viral illnesses, and/or had a CT or MRI scan showing an absence of tissue connecting the brain to the pituitary gland (the pituitary stalk).*

## MYTHS

The following statements are **NOT TRUE** according to current research:

- ONH occurs in clusters due to use of pesticides in the environment.
- The associated midline brain anomalies have a profound effect on the visual outcome and/or spatial orientation of these patients.
- All mothers of children with ONH were drug users during pregnancy.

## TEACHING STRATEGIES

- Each child should receive medical monitoring and comprehensive, ongoing, functional and educational assessment.
- Teachers need to increase the size, contrast, and lighting of materials for a child who has nystagmus and bilateral severe visual loss because of generally depressed fields.
- When a specific field loss is identified, materials need to be presented within the child's visual field. The child should be encouraged to turn his head to look for people and objects outside his visual field.
- A child with ONH needs the opportunity to develop learned aspects of depth perception through fine and gross motor activities, including container play, nesting and stacking, ball tossing and rolling, pouring activities, and lots of practice with stairs, slides, foam wedges for crawling, and cardboard box play.

- The effects of light sensitivity can be minimized by adjusting lighting levels, wearing tinted lenses, and minimizing glare on surfaces.
- A child with ONH often has other conditions that need to be considered when developing an individual education plan.
  - A child who is easily distracted, frustrated, disorganized, and impulsive may be helped by predictable physical environments, dependable daily routines, and limited distractions.
  - Slowing the pace of activities and providing predictable transition routines may help reduce resistant and irritable behavior.
  - Offering frequent snacks to children diagnosed with hypoglycemia may be helpful.
- When a child does have feeding problems, parents and professionals need to agree on recommended strategies to create a positive feeding experience.
- When a child has no functional vision, an approach that uses all the senses for learning is needed.
- Evaluation by an instructor of Orientation and Mobility is essential in meeting the child's needs, due to loss of detail vision and vision field loss.

## **GLOSSARY**

1. 1. Amblyopia: a reversible condition affecting visual acuity that can lead to loss of vision in an eye that is structurally capable of seeing.
2. 2. Anencephaly: a birth defect in which all but the most primitive part of the brain, spinal cord, and overlying bones of the skull are absent.
3. 3. Corpus Callosum: a mass of white matter that joins the cerebral hemispheres of the brain, allowing them to communicate with each other.
4. 4. Encephalocele: a birth defect in which the brain protrudes through an opening in the skull.
5. 5. Perinatal: describes the period between 28 weeks gestation through the first week following delivery.
6. 6. Radiographic: refers to a picture produced on a sensitive surface by a form of radiation other than light.
7. 7. Septo optic dysplasia: a syndrome which includes midline abnormalities of the brain and optic nerve hypoplasia.
8. 8. Visual Acuity: ability of the eye to see clearly (which can be measured specifically), to perceive objects and to see detail within central vision.

## RESOURCES

Borchert, M.S. An Inside Look At Optic Nerve Hypoplasia Research - A Leading Cause of Infant Blindness, USC School of Medicine.

Hoyt, C. (1986). Optic Nerve Hypoplasia: A Changing Perspective. Transactions of the New Orleans Academy of Ophthalmology. Raven Press, New York.

Lambert, S. & Hoyt, C. (1987). Optic Nerve Hypoplasia. Ophthalmology. 32, #1, July, August, 1-9.

Marsh-Tootle, W.L. (1994). Congenital Optic Nerve Hypoplasia: A Symposium Paper. Optometry & Vision Science. 71; #3, 174-180.

Tait, P. (1989). Optic Nerve Hypoplasia: A Review of the Literature, Journal of Visual Impairment and Blindness, April, 207-211.

Willnow, S. et al. (1996). Endocrine disorders in septo-optic dysplasia (De Morsier syndrome)-evaluation and follow up of 18 patients. European Journal of Pediatrics, 155; 179-184.

## ACKNOWLEDGMENTS

Project Coordinators: Julie Bernas-Pierce, M.Ed. and Namita Jacob  
Dr. Creig Hoyt, Nancy Akeson, Gail Calvello, Laila Adle,  
Carole Osselaer, Patricia Silva, Laura Davis.

Reviewers: Kay Ferrell, Ph.D., Deborah Hatton, Ph.D., Kathryn Neale Manalo

The Pediatric Visual Diagnosis Fact Sheets are sponsored by a grant from the Blind Children's Center and with support from the Hilton/Perkins Program through a grant from the Conrad Hilton Foundation of Reno, Nevada.

REPRODUCTION FOR RESALE IS STRICTLY PROHIBITED (1/98 BBF)



### **BLIND BABIES FOUNDATION**

1814 Franklin St, 11<sup>th</sup> Floor  
Oakland, CA 94612 (510)446-2229  
[www.blindbabies.org](http://www.blindbabies.org)